

## Transdermal CO<sub>2</sub> Increases Perfusion Index in Patients with Placenta Accreta Following Temporary Abdominal Aortic Cross-Clamping

Gracelia Damanik<sup>1\*</sup>, ItoPuruhito<sup>1\*</sup>, Rozi Aditya Aryananda<sup>2</sup>, Pudji Lestari<sup>3</sup>, Heroe Soebroto<sup>3</sup>, Oky Revianto<sup>1</sup>

<sup>1</sup>Cardio-Thoracic and Vascular Surgery Department, Faculty of Medicine, Universitas Airlangga - Soetomo General Academic Hospital, Surabaya, Indonesia

<sup>2</sup>Obstetric and Gynecology Department, Faculty of Medicine, Universitas Airlangga - Soetomo General Academic Hospital, Surabaya, Indonesia

<sup>3</sup>Public Health Department, Faculty of Medicine, Universitas Airlangga - Soetomo General Academic Hospital, Surabaya, Indonesia

\*graceliadamanik@gmail.com (GD) and itopuruhito@yahoo.co.id (PI)

### ABSTRACT

Clinal management for patients with placental accreta could involve surgeries with the risk of massive bleeding. To overcome, the use of abdominal aortic cross-clamping is suggested. Nonetheless, the procedure could cause ischemic complications with worsening tissue perfusion. In this present study, the transdermal CO<sub>2</sub> was used as a mean to recover the tissue perfusion of placental accreta patients following the abdominal aortic cross-clamping. The transdermal CO<sub>2</sub> was administered via non-invasive vaporization technique accommodated by deoxyhemoglobin vasodilator (D'Oxyva). The perfusion indices (PIs) from each time of post-abdominal aortic cross-clamping (0-30 minutes) were measured using an oximeter as an indicator for tissue perfusion. Our data suggested that the mean PIs in treatment group were significantly higher than in the control group at all observation times ( $p < 0.001$ ). The mean PIs during and after abdominal aortic cross-clamping in treatment group was 5.6-fold higher than control group ( $p < 0.001$ ). Overall, the results suggest that transdermal CO<sub>2</sub> could improve the tissue perfusion after the abdominal aortic cross-clamping procedure in placental accreta patients.

**Keywords:** Transdermal carbon dioxide, peripheral perfusion, placenta accreta, caesarean section, microcirculation

### Introduction

Incidence of multifactorial placental accreta has increased from 0.8 up to 3 of 1000 deliveries in the last decade.<sup>1</sup> The risk of placental accreta in pregnant women who have not received cesarean section is 0.03%, and the risk increases to 4.7% in pregnant women with a clinical history of cesarean section.<sup>2</sup> Patients with placental accreta could be treated conservatively or surgically, depending on the severity.<sup>3</sup> During the surgery, the blood oozing may occur due to the presence of massive collateral vascular. In order to manage the bleeding, the temporary aortic cross-clamping procedure was introduced.<sup>4</sup> Based on the report<sup>4</sup> and the practices in Regional Public Hospital (RSUD) Dr. Soetomo, Surabaya, Indonesia, the aortic cross-clamping procedure could significantly reduce the bleeding (unpublished).

Nonetheless, the application of the temporary abdominal aortic cross-clamping could cause ischemic complications and affect distal organs.<sup>5, 6</sup> Moreover, it is suggested that aortic clamping could lead to left ventricular decompensation and failure concomitant to the increase in myocardial oxygen demand and alteration of blood volume.<sup>7</sup> The ischemic process occurs progressively along with the increase of the cross-clamping duration. Hence, it is important to improve the micro-circulation post-aortic cross-clamping. In this regard, transdermal CO<sub>2</sub> could be administered, inducing the release of O<sub>2</sub> from hemoglobin into

surrounding tissues ascribed to the difference in affinity (known as Bohr and Haldane effect).<sup>8-10</sup>

Herein, the transdermal CO<sub>2</sub> were non-invasively administered to pregnant patients suffering from placental accreta after receiving temporary abdominal aortic cross-clamping. The aqueous CO<sub>2</sub> is absorbed through the skin and to the vascular system via vaporization mechanism.<sup>11</sup> According to a study using rat model,<sup>12</sup> the administration of transdermal CO<sub>2</sub>, in a form of hydrogel, could increase the partial pressure of O<sub>2</sub> in the tissue and capillary owing to the release of nitric oxide (NO) in capillary endothelial cells-produced tissues. Increase in NO induced vasodilation in capillary which lead to a better tissue perfusion. The use of transdermal CO<sub>2</sub> post-aortic cross-clamping procedure has been reported previously with significant improvement in tissue perfusion.<sup>13-15</sup> Nonetheless, its use in placental accreta patients is scarcely reported. The aim of this study was to assess the role of the transdermal CO<sub>2</sub> to recover the tissue perfusion in placental accreta patients. This study has a novelty of taking the placental accreta into account.

## Methods

### Study design

This quasi experiment aimed to evaluate the effect of the transdermal CO<sub>2</sub> administration in patients suffering placental accreta who underwent temporary abdominal aortic cross-clamping procedure. This study was conducted in RSUD Dr. Soetomo, Surabaya, Indonesia, within the range of July to December, 2020. In total, 30 patients recruited in this study, randomly assigned to control group (15) and treatment group (15). All patients voluntarily signed the informed consent prior to the study. Transdermal CO<sub>2</sub> was administered to the patient using deoxyhemoglobin vasodilator (D'Oxyva) on the patient's thumb, where the value of perfusion index (PI) was then calculated following the cross-clamping removal. PI values were recorded five time using an oximeter after the removal of cross-clamping during the first 30 min (5, 10, 20 and 30 min, as suggested previously.<sup>16</sup> PI values during and after the cross-clamping procedure were also measured in each group.

Patients with placental accreta index (PAI), based on ultrasonography analysis, were included in this study. The patients either underwent cesarean section or hysterectomy with temporary abdominal aortic cross-clamping. Patients suffering from other comorbidities (gestational diabetes, eclampsia, and preeclampsia) were also included. Pregnant women suffering from anemia with hemoglobin > 7 g/dL could participate in the study. Meanwhile, patients were excluded from the study if they experienced: hemorrhagic shock, sepsis and sepsis shock, hemostasis disorders, respiratory disorder from corona virus diseases-19 (COVID-19), and peripheral vascular disease or obstructive peripheral arterial disease.

### Data collection and analysis

The data were presented in mean and standard deviation (SD), and then tested using Kolmogorov-Smirnov normality test to assess the normality of the data. Non-parametric test, Mann-Whitney U, was used for data with non-normal distribution to compare the different between the control and treatment groups. To compare the PI values during and after the cross-clamping procedure within the group independent *T*-test, to compare the difference of mean PI between control and experimental groups. All data analysis was carried out in SPSS v23 (SPSS Inc., Chicago, IL, USA).

### Ethical clearance

The protocol of the study was approved by Institutional Ethics Committee of Soetomo General Academic Hospital, Surabaya (no 0142/KEPK/II/2021).

### Results

#### Patients' characteristics

Characteristics of subjects participating in this research has been presented (Table 1). The age of patients in experimental group is older than in control group. Patients in control group experience more blood loss ( $1208.67 \pm 562.478$  mL) compared to that in experimental group ( $818.67 \pm 172.007$  mL). In control group, patients undergoing abdominal aortic cross-clamping with a longer duration than that in experimental group.

Table 1. Characteristics of placental accreta patients undergoing abdominal aortic cross-clamping

Parameter	Control (Mean $\pm$ SD)	Experimental (Mean $\pm$ SD)
Age (years old)	$33.00 \pm 3.464$	$34.53 \pm 5.014$
Blood loss (mL)	$1208.67 \pm 562.478$	$818.67 \pm 172.007$
Duration of abdominal aortic cross-clamping (min)	$86.33 \pm 34.879$	$77.00 \pm 22.662$

#### Effect of transdermal CO<sub>2</sub> on perfusion

According to Kolmogorov-Smirnovtest, the distribution of the mean PIs among control and experimental groups were not distributed normally. Therefore, Mann-Whitney U test was used to compared the PIs between the two groups. The results are presented in Table 2. The test revealed that PI values after the temporary abdominal aortic cross-clamping of in treatment group were significantly higher compared to that of control group ( $p < 0.001$ ). At the 0min post-aortic cross-clamping removal, the mean PI in the treatment group was 4.45-fold higher than control group. The difference of PI values was even higher at the end of the observation, where the mean value of treatment group was 7.74-fold higher than control group. In control group, the increase of PI values was rather fluctuating (decrease to  $0.29 \pm 0.08$  from the initial  $0.33 \pm 0.09$ ). Yet, in patients receiving transdermal CO<sub>2</sub>, the PI values increased gradually (from  $1.47 \pm 0.07$  at 0 min to  $2.71 \pm 0.25$  at 30 min).

Table 2. Perfusion index(PI) values of control and treatment group measured after the temporary abdominal aortic cross-clamping

Time post-cross-clamping	Perfusion index (PI)		
	Control (Mean $\pm$ SD)	Treatment(Mean $\pm$ SD)	<i>p</i> -value
0 min	$0.33 \pm 0.09$	$1.47 \pm 0.07$	$<0.001^*$
5 min	$0.33 \pm 0.19$	$1.62 \pm 0.12$	$<0.001^*$
10 min	$0.36 \pm 0.12$	$2.13 \pm 0.33$	$<0.001^*$
20 min	$0.29 \pm 0.08$	$2.48 \pm 0.32$	$<0.001^*$
30 min	$0.35 \pm 0.04$	$2.71 \pm 0.25$	$<0.001^*$

\*Statistically significant at  $p < 0.001$

This study also observed the changes of PI values during and after the temporary abdominal aortic cross-clamping (Figure 1). In control group, the PI values during and after the cross-clamping removal reached a mean difference of  $0.30 \pm 0.02$ . Meanwhile in treatment or experimental group, the mean difference was higher ( $1.68 \pm 0.23$ ). The difference in treatment

group was 5.6 times control group. Based on independent t-test, the difference was significantly different higher in treatment group compared to control group with  $p < 0.001$ .

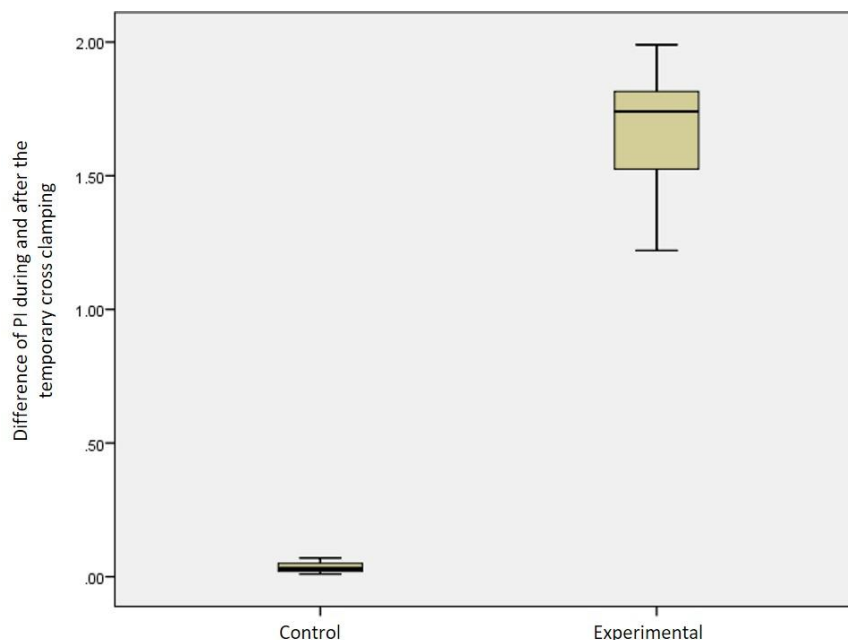


Figure 1. Comparison of PI value changes during and after the temporary cross-clamping in control and experimental groups.

### Discussion

In the case of placental accreta, massive collateral vascular may be found, in particular in posterior bladder and pelvic ligaments, that requires a ligation.<sup>3</sup> Collateral vascular may act as the source of blood oozing during uterus dissection of perimetrium or surrounding visceral organs. Hence, temporary abdominal aortic cross-clamping as high as infrarenal was applied to stop the bleeding. The cross-clamping was conducted using Cosgrove flex clamp and vascular tape to preserve the abdominal aorta.<sup>4</sup> Within the last three years, this cross-clamping management has been conducted in 39 patients in Dr. Soetomo Hospital, Surabaya, Indonesia. The results were satisfying, as the cross-clamping with averaged duration of 106 min yielded a significant decrease in bleeding.

However, temporary abdominal aortic cross-clamping procedure could generate temporary ischemic in lower extremity, as reported previously.<sup>17</sup> Upon the release of abdominal aortic cross-clamping, the level of oxygenated hemoglobin decrease with the increase in deoxygenated hemoglobin was also reported.<sup>18</sup> In the same study, the reduction of total oxygenation index (TOI) and the elevation of lactic acid-induced blood acidity were observed.<sup>18</sup> These findings suggest the presence of anaerobic metabolism in the distal organ owing to the abdominal aortic cross-clamping. To reduce the risk of this complication, transdermal CO<sub>2</sub> could be administered to the patients.

CO<sub>2</sub> has a vasodilatation effect against blood vessels, called as active hyperaemia.<sup>19</sup> The phenomenon was also known as Bohr and Haldane effect; interaction between O<sub>2</sub> and CO<sub>2</sub> toward hemoglobin, where partial pressure from CO<sub>2</sub> induces the dissociation of O<sub>2</sub> in hemoglobin and releases it to the surrounding tissue.<sup>8-10</sup> Based on this principle, the application of transdermal CO<sub>2</sub> is expected to repair the aortic cross-clamping-affected local micro-circulation (capillary circulation) that consequently improves the blood flow and tissue

perfusion. Transcutaneous CO<sub>2</sub> therapy has been reported effective in improving the micro-circulation disruption in peripheral arterial diseases (such as diabetic angiopathy and Raynaud disease).<sup>13</sup> Another study reported the improvement in micro-vascular diameter, blood flow, and partial pressure of arterial O<sub>2</sub>.<sup>14</sup> Increase in vascular endothelial growth factor was also reported upon the administration of transdermal CO<sub>2</sub>.<sup>15</sup>

In this study, improvement of micro-circulation was suggested by the increase of transdermal CO<sub>2</sub>-induced PIs following the abdominal aortic cross-clamping procedure. This is in the same agreement with Bohr and Haldane effect, where peripheral hypercapnia stimulates the vasodilatation and tissue perfusion. According to the previous study, this phenomenon is responsible for the acceleration of wound recovery at the lower leg.<sup>14</sup> A study suggest that the transdermal CO<sub>2</sub> could increase significantly partial pressure of capillary oxygen as high as 25-45 mmHg (p<0.001), along with 10-20 mg/dL increase in deoxygenated hemoglobin as the consequence of O<sub>2</sub> release from hemoglobin.<sup>8</sup> Another study measuring arterial pressure of lower extremity using Laser Doppler Flux (LDflux) also confirmed the role of transdermal CO<sub>2</sub> administration in improving tissue perfusion (p<0.05).<sup>19</sup> Moreover, the increase in partial pressure of O<sub>2</sub> could reduce the pH level in the capillary causing a vasomotor effect; a capillary vasodilatation that improves the perfusion index in the tissue.<sup>12</sup> Furthermore, a study also suggested the absence of adverse event upon the administration of transdermal CO<sub>2</sub> *in vivo*.<sup>14</sup>

This study has some limitations. The number of samples is relatively small. In addition, the outcome of patients was not followed and reported. The diagnoses of the patients were relatively varied due to small number of patients received the abdominal aortic cross-clamping upon placental accreta in Dr. Soetomo Hospital, Surabaya, Indonesia.

### Conclusions

Our findings suggest that the administration of transdermal CO<sub>2</sub> could improve the perfusion index of undergoing surgical treatment with temporary abdominal aortic cross-clamping upon placental accreta diagnosis.

### References

1. Jauniaux E, Bhide A, Kennedy A, Woodward P, Hubinont C, Collins S, et al. FIGO consensus guidelines on placenta accreta spectrum disorders: Prenatal diagnosis and screening. *Int J Gynaecol Obstet.* 2018; 140:274-80.
2. Belfort MA. Placenta accreta. *Am J Obstet Gynecol.* 2010; 203:430-9.
3. Jauniaux E, Hussein AM, Fox KA, Collins SL. New evidence-based diagnostic and management strategies for placenta accreta spectrum disorders. *Best Pract Res Clin Obstet Gynaecol.* 2019; 61:75-88.
4. Chou M-M, Ke Y-M, Wu H-C, Tsai C-P, Ho ES-C, Ismail H, et al. Temporary Cross-clamping of the Infrarenal Abdominal Aorta During Cesarean Hysterectomy to Control Operative Blood Loss in Placenta Previa Increta/Percreta. *Taiwanese Journal of Obstetrics and Gynecology.* 2010; 49:72-6.
5. Nissinen J, Biancari F, Wistbacka JO, Peltola T, Lopenen P, Tarkiainen P, et al. Safe time limits of aortic cross-clamping and cardiopulmonary bypass in adult cardiac surgery. *Perfusion.* 2009; 24:297-305.
6. Doenst T, Borger MA, Weisel RD, Yau TM, Maganti M, Rao V. Relation between aortic cross-clamp time and mortality--not as straightforward as expected. *Eur J Cardiothorac Surg.* 2008; 33:660-5.
7. Cuzick LM, Lopez AR, Cooper JR. Pathophysiology of Aortic Cross-clamping. *Thoraco-Abdominal Aorta* 2011. p. 65-72.

8. Sakai Y, Miwa M, Oe K, Ueha T, Koh A, Niikura T, et al. A novel system for transcutaneous application of carbon dioxide causing an "artificial Bohr effect" in the human body. *PLoS One*. 2011; 6:e24137.
9. Hlastala MP, Woodson RD. Saturation dependency of the Bohr effect: interactions among H<sup>+</sup>, CO<sub>2</sub>, and DPG. *J Appl Physiol*. 1975; 38:1126-31.
10. Ito T, Moore JI, Koss MC. Topical application of CO<sub>2</sub> increases skin blood flow. *J Invest Dermatol*. 1989; 93:259-62.
11. Csonka A, Gargyan I, Varga E. Multidisciplinary treatment of a complicated crural degloving injury in a diabetic patient. *Injury*. 2021; 52 Suppl 1:S74-S7.
12. Penhavel MV, Nascimento VH, Duraes EF, Carneiro FP, Sousa JB. Effects of carbon dioxide therapy on the healing of acute skin wounds induced on the back of rats. *Acta Cir Bras*. 2013; 28:334-9.
13. Wollina U, Heinig B, Uhlemann C. Transdermal CO<sub>2</sub> application in chronic wounds. *Int J Low Extrem Wounds*. 2004; 3:103-6.
14. Brandi C, Grimaldi L, Nisi G, Brafa A, Campa A, Calabrò M, et al. The role of carbon dioxide therapy in the treatment of chronic wounds. *In Vivo*. 2010; 24:223-6.
15. Frangez I, Colnaric J, Truden D. Use of Transcutaneous Application of CO<sub>2</sub> in Diabetic Foot Pathology. *Clinical Research on Foot & Ankle*. 2017; 05.
16. He HW, Liu DW, Long Y, Wang XT. The peripheral perfusion index and transcutaneous oxygen challenge test are predictive of mortality in septic patients after resuscitation. *Crit Care*. 2013; 17:R116.
17. Boezeman RPE, Kelder JC, Waanders FGJ, de Vries JPPM. Continuous Surveillance of Lower Limb Perfusion During Aortic Surgery With Near-Infrared Spectroscopy: A Pilot Study. *Vascular and Endovascular Surgery*. 2011; 45:407-11.
18. Sako H, Hadama T, Miyamoto S, Anai H, Wada T, Iwata E, et al. Limb ischemia and reperfusion during abdominal aortic aneurysm surgery. *Surg Today*. 2004; 34:832-6.
19. Finzgar M, Melik Z, Cankar K. Effect of transcutaneous application of gaseous carbon dioxide on cutaneous microcirculation. *Clin Hemorheol Microcirc*. 2015; 60:423-35.